

# Electroconvulsive therapy reduces frontal cortical connectivity in severe depressive disorder

Jennifer S. Perrin<sup>a,1</sup>, Susanne Merz<sup>b</sup>, Daniel M. Bennett<sup>a</sup>, James Currie<sup>a</sup>, Douglas J. Steele<sup>c</sup>, Ian C. Reid<sup>a</sup>, and Christian Schwarzbauer<sup>b</sup>

<sup>a</sup>Applied Health Sciences (Mental Health), University of Aberdeen, Royal Cornhill Hospital, Aberdeen AB25 2ZH, United Kingdom; <sup>b</sup>Aberdeen Biomedical Imaging Centre, University of Aberdeen, Foresterhill, Aberdeen AB25 2ZD, United Kingdom; and <sup>c</sup>Division of Neuroscience, Medical Research Institute, University of Dundee, Ninewells Hospital and Medical School, Dundee DD1 9SY, United Kingdom

Edited by Marcus E. Raichle, Washington University in St. Louis, St. Louis, MO, and approved February 14, 2012 (received for review October 18, 2011)

**To date, electroconvulsive therapy (ECT) is the most potent treatment in severe depression. Although ECT has been successfully applied in clinical practice for over 70 years, the underlying mechanisms of action remain unclear. We used functional MRI and a unique data-driven analysis approach to examine functional connectivity in the brain before and after ECT treatment. Our results show that ECT has lasting effects on the functional architecture of the brain. A comparison of pre- and posttreatment functional connectivity data in a group of nine patients revealed a significant cluster of voxels in and around the left dorsolateral prefrontal cortical region (Brodmann areas 44, 45, and 46), where the average global functional connectivity was considerably decreased after ECT treatment ( $P < 0.05$ , family-wise error-corrected). This decrease in functional connectivity was accompanied by a significant improvement ( $P < 0.001$ ) in depressive symptoms; the patients' mean scores on the Montgomery Asberg Depression Rating Scale pre- and posttreatment were 36.4 (SD = 4.9) and 10.7 (SD = 9.6), respectively. The findings reported here add weight to the emerging "hyperconnectivity hypothesis" in depression and support the proposal that increased connectivity may constitute both a biomarker for mood disorder and a potential therapeutic target.**

mental health | neuroimaging | antidepressant | cognitive function

The treatment of depressive disorder is one of the most pressing issues in contemporary medical practice: The illness is a leading cause of significant disability worldwide (1). Current therapeutic strategies are imperfect, and there is an urgent need to develop more consistently effective and rapidly acting treatment solutions. Unfortunately, our understanding of the etiology of mood disorder is incomplete. As a result, the elucidation of the mechanisms of action of effective treatment has necessarily been less than secure and advance has been slow. Available treatments (e.g., chemical antidepressant therapy) were discovered serendipitously rather than designed, and insight into the biology of depressive disorder by study of antidepressant actions has been limited. In particular, the effectiveness of electroconvulsive therapy (ECT), the most potent and rapidly acting of all antidepressant agents (2), has eluded a coherent explanatory framework despite its regular use for more than 70 years. However, if the effects of ECT could be reproduced in a less invasive way, and with a more benign side-effect profile, the treatment of severe depression would be significantly enhanced. To achieve this, we need first to understand better how ECT influences brain function. Here, we show that ECT alters the functional architecture of frontal systems by strongly down-regulating connectivity in key circuits implicated in mood disorder.

Efforts to delineate the neural substrate of mood disorder using functional brain imaging technology have generally identified abnormal frontal cortical and limbic activity in depressed patients (3–9). Although such regional findings tend to correspond anatomically to those brain areas maximally activated by diverse emotional tasks in normal individuals (10), the nature (over- or underactivity) of the dysfunction seen in depressed subjects has

seemed contradictory at times and its significance uncertain. Several recent functional imaging studies have focused on the investigation of functional connectivity among cortical and corticolimbic networks rather than the description of stimulus-induced or task-related activity in individual regions of interest (11–13).

Connectivity abnormalities have been described in a range of functional networks hypothesized to play a role in the generation of mood symptoms in depressed patients. Such networks have been characterized on the basis of their anatomical components and the functions they subservise, and defined by their measurable relationships to candidate seed regions as revealed by strong temporal correlations in blood oxygen level-dependent signals detected by functional MRI (fMRI) when the brain is not engaged in a specific cognitive task (14). In particular, Sheline et al. (11) have shown that three networks (the affective network, the cognitive control network, and the default mode network), each implicated in different aspects of mood disorder, not only show increased intrinsic resting state connectivity in depressed patients compared with healthy controls but further share increased connectivity to a common component in the dorsal medial prefrontal cortex that they term the dorsal nexus. They hypothesized that a reduction in regional connectivity might prove an important therapeutic target in the treatment of depression.

Subsequent findings from treatment studies are consistent with this idea. Healthy volunteers taking chemical antidepressants have been shown to have reduced connectivity between the amygdala and frontal regions compared with subjects taking placebo (with different frontal connectivity patterns observed for serotonin and noradrenaline reuptake inhibitors) (13), and higher pretreatment orbitofrontal cortex connectivity levels may predict a positive response to antidepressants in depressed patients (12).

There is thus an emerging hypothesis that pathological "hyperconnectivity" among intracortical and corticolimbic circuits underlies important aspects of depressive disorder. Predictably, precise anatomical correlation patterns in reports vary with the candidate seed regions used to define the networks chosen for investigation and the nature of the comparisons being made (e.g., sufferers vs. healthy controls; "treatment" effects vs. placebo in healthy subjects, and within-subject effects before and after treatment in depressed patients).

In the present study, we examined the impact of ECT on connectivity in nine patients successfully treated for severe depressive disorder by comparing functional connectivity in the whole brain before and after therapy using fMRI. Rather than

Author contributions: J.S.P., D.M.B., D.J.S., and I.C.R. designed research; J.S.P., D.M.B., J.C., and I.C.R. performed research; S.M. and C.S. contributed new analytic tools; J.S.P., S.M., I.C.R., and C.S. analyzed data; and J.S.P., S.M., I.C.R., and C.S. wrote the paper.

The authors declare no conflict of interest.

This article is a PNAS Direct Submission.

Freely available online through the PNAS open access option.

<sup>1</sup>To whom correspondence should be addressed. E-mail: j.perrin@abdn.ac.uk.

This article contains supporting information online at [www.pnas.org/lookup/suppl/doi:10.1073/pnas.1117206109/-DCSupplemental](http://www.pnas.org/lookup/suppl/doi:10.1073/pnas.1117206109/-DCSupplemental).

investigating effects on networks derived from the prior specification of candidate seed regions, we calculated the average global functional connectivity of each voxel with all the other voxels in the brain based on temporal signal correlation, comparing findings before and after treatment. This permitted an unbiased, data-driven analysis of treatment effects and the identification of a target region of interest that exhibited a significant decrease in connectivity after treatment. This region was then used to determine the associated functional brain networks (i.e., the brain areas to which this region was functionally connected before and after treatment).

### Results

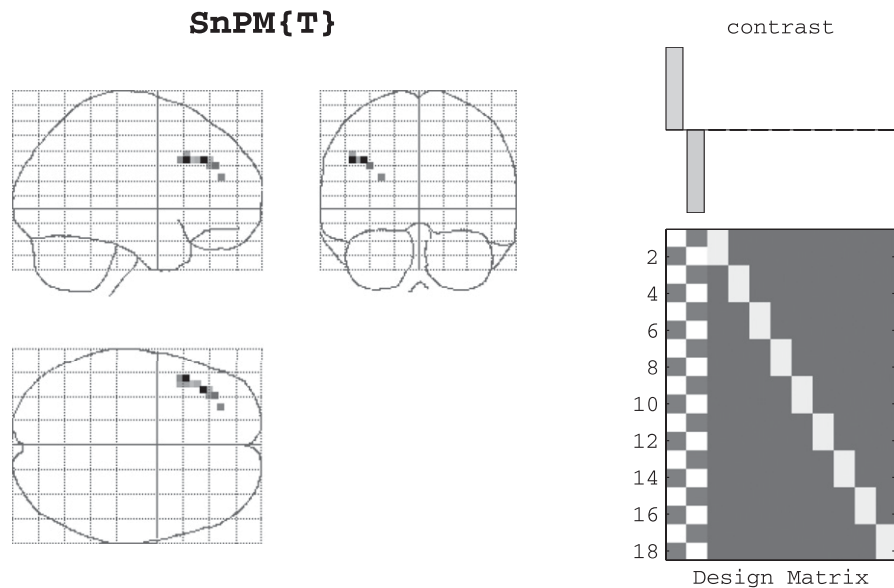
A comparison of pre- and posttreatment functional connectivity data revealed a significant and unexpectedly restricted cluster of voxels in and around the left dorsolateral prefrontal cortex (DLPFC) region (Fig. 1), where the average global functional connectivity was considerably decreased after ECT treatment [ $P < 0.05$ , family-wise error (FWE)-corrected]. Fig. 2 shows a 3D orthogonal representation of this cluster, which extends into Brodmann areas (BAs) 44, 45, and 46.

The average global functional connectivity, also known as weighted global connectivity (WGC), is a quantitative parameter that tells us to what extent each voxel is connected to all other voxels in the brain (Methods). The observed reduction in the average global functional connectivity therefore means that for each voxel within the cluster shown in Figs. 1 and 2, the average connectivity with all other voxels in the brain was significantly reduced after ECT treatment. To localize the spatial distribution of these

connectivity changes, an additional analysis was performed. The statistically generated cluster was used as a seed region to determine the associated functional brain networks [i.e., the brain areas to which the seed region was functionally connected before and after ECT treatment (Methods)]. The results of this analysis are summarized in Fig. 3. Areas that exhibited significant functional connectivity ( $P < 0.001$ , FWE-corrected) with the seed region before ECT treatment are shown in orange, whereas areas in which significant functional connectivity persisted after ECT treatment are shown in cyan; note that no voxels were found that were significantly connected after but not before ECT treatment. Fig. 3 reveals that ECT treatment had significantly reduced connectivity between medial cortex structures (anterior cingulate, BAs 24 and 32; medial frontal cortex, BA 8); DLPFCs bilaterally (BA 9 extending to BAs 6, 44, and 45); and a unilateral (left) region in the supermarginal gyrus, angular gyrus, and somatosensory association cortex (BAs 7, 39, and 40). This observed decrease in functional connectivity was accompanied by a significant reduction in depressive symptoms (Fig. 3, bar chart). The patients' mean score on the Montgomery Asberg Depression Rating Scale (MADRS) before treatment was 36.4 (SD = 4.9), indicating severe depression. The mean score after treatment was 10.7 (SD = 9.6). This significant ( $P < 0.001$ ) reduction in depressive symptoms of 25.8 points (SD = 11.6) indicates a very substantial and typical response to ECT treatment.

### Discussion

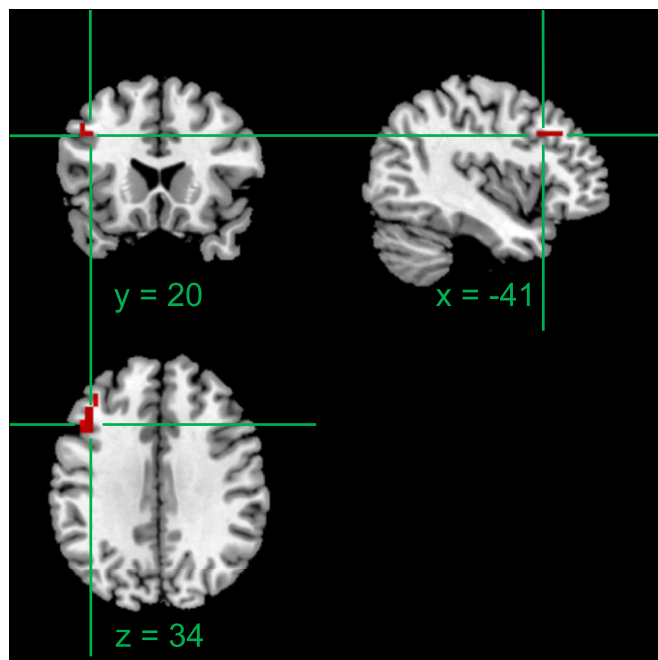
The impact of ECT on global functional connectivity change (as opposed to the many reported widespread effects on other aspects



#### P values & statistics: Weighted Global Connectivity

cluster-level	voxel-level				x, y, z mm			
	k	$P_{FWE-corr}$	$P_{FDR-corr}$	T				$P_{uncorr}$
11	11	0.0137	0.0620	11.49	0.0020	-38	32	34
		0.0137	0.0620	11.47	0.0020	-46	20	34
		0.0293	0.0620	10.32	0.0020	-34	40	30
1	1	0.0313	0.0620	10.08	0.0020	-26	44	22

**Fig. 1.** Significant reduction in the average global functional connectivity after ECT treatment in a group of severely depressed patients ( $n = 9$ ). A significant decrease ( $P < 0.05$ , FWE-corrected) was observed in a cluster of voxels in and around the left DLPFC region (BAs 44, 45, and 46). Results were obtained by means of a nonparametric permutation test comparing post- and pretreatment global connectivity data on a voxel-by-voxel basis.



**Fig. 2.** 3D orthogonal representation of the left DLPFC cluster of voxels (shown in red) for which a significant reduction in the average global functional connectivity was observed after ECT treatment (Fig. 1). The coordinates ( $x$ ,  $y$ , and  $z$ ) refer to Montreal Neurological Institute standard space.

of brain function) appears remarkably restricted and lateralized, limited to an area within the left DLPFC. This finding is consistent with long-standing recognition that the DLPFC is an executive component of brain circuitry implicated in depressive disorder and cognitive function (10, 15), both of which are substantially affected by ECT (2), whereas the laterality of the finding mirrors asymmetries in DLPFC activity in depressed patients (16). The connectivity map obtained using this DLPFC region as a seed region for a connectivity analysis with the pretreatment fMRI data (Fig. 3, area displayed in orange) includes the corresponding portion of the right DLPFC; the more dorsal part of the medial prefrontal cortex and anterior cingulate; and portions of the left supramarginal gyrus, angular gyrus, and somatosensory association cortex. Functional connectivity between the DLPFC and these areas was selectively reduced following ECT treatment (Fig. 3, area displayed in cyan). These regional effects are consistent with general formulations of the neuroanatomy of mood disorder based on activation studies (3–9), which emphasize dysfunctional relationships between cortical and limbic structures. With regard to studies of treatment effects, reductions in functional connectivity observed here encompass the region lesioned in anterior cingulotomy for severe treatment-resistant depressive disorder (17), those areas stimulated in rapid-rate transcranial magnetic treatment for depression (18), and parallel aspects of the impact of cognitive behavioral therapy (19). The observed effects were entirely intracortical [including changes in functional connectivity between the neocortex and limbic cortex (e.g., DLPFC, anterior cingulate)], in contrast to connectivity studies exploring chemical antidepressant therapy, where subcortical limbic structures are implicated (12, 13). Strikingly, the medial areas to which connectivity has been reduced (Fig. 3) also include the so-called dorsal nexus, recently described by Sheline et al. (11) as an area of common hyperconnectivity between the three networks, which exhibited pathologically increased connectivity in mood disorder in their study of depression. We propose here that ECT acts to reduce the contribution of DLPFC to the hypothesized nexus of

pathological connectivity, restoring aspects of emotional function yet simultaneously generating the cognitive side effects of ECT.

Considering the asymmetry of our findings, the lateralized impact of ECT is generally consistent with an extensive literature recording interhemispheric imbalance in mood disorder. Functional studies using neuropsychological, psychophysiological, and imaging methods suggest hyperactivation of right frontal areas and hypoactivation of left frontal systems, whereas studies of unilateral brain lesions (stroke, tumors, and epilepsy) have often, although not exclusively, implicated left hemisphere dysfunction in mood disorder (reviewed in 20). It is tempting to speculate that ECT might act to rebalance hemispheric activity through modulation of connectivity, but the data presented here cannot confirm or refute this notion.

Given that successful chemical antidepressant therapy does not have a similar effect on cognitive function, the spectrum of connectivity effects seen here may differ in detail from those associated with antidepressant therapy. Indeed, efforts to dissociate cognitive side effects from the therapeutic actions of ECT have proven problematic, with therapeutic efficacy tending to correlate with cognitive dysfunction even when using unilateral ECT (where the nondominant hemisphere is stimulated in treatment). Although this procedure may spare cognitive function to a degree, right unilateral electrode placement tends to be less effective than bilateral ECT (2) and less rapidly acting than left unilateral ECT [in dextral subjects (21)]. All the patients in this study received bilateral ECT. It is of interest, given the left-sided laterality of our connectivity findings, that the majority of patients receiving unilateral ECT have the stimulus applied to right hemisphere (because most are left hemisphere-dominant). Speculatively, this may explain both the cognitive sparing effects and the reduced efficacy of right unilateral ECT, given our similarly lateralized findings.

It may be hypothesized that lessening the DLPFC contribution to the proposed “nexus” among mood disorder-relevant circuits may lessen the pathological impact of dysfunction of all of them on affective function, but this requires further investigation. Although the statistical effects are highly significant, the sample size is small. This reflects the difficulty in recruiting severely depressed patients receiving ECT for studies requiring repeated imaging, and replication is required. Further, although patients had failed to respond to psychotropic medication, they continued to take it and medication effects cannot be ruled out. Similarly, patients received repeated anesthesia (propofol), and a muscle relaxant (suxamethonium) was administered in the course of ECT.

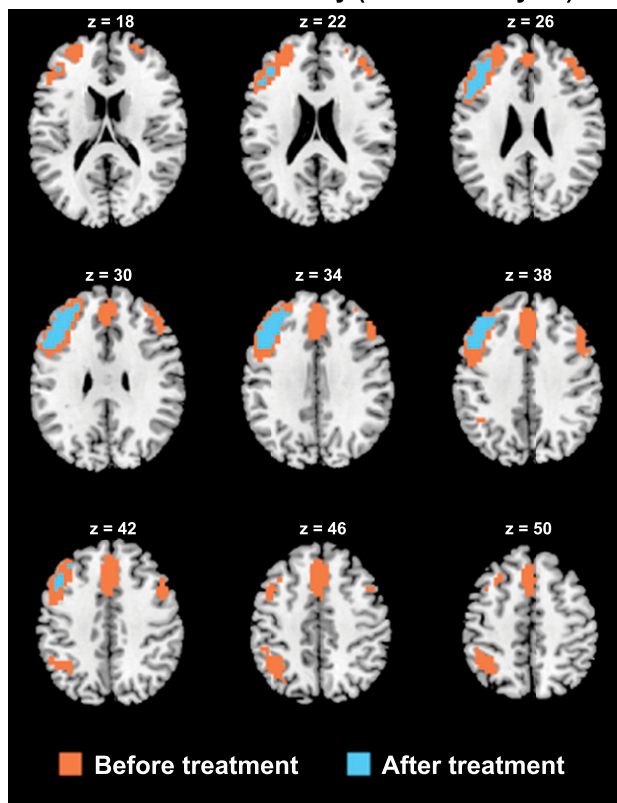
Future studies should examine longitudinal changes in connectivity, particularly in those patients who subsequently relapse, and compare patterns of connectivity change across a range of physical and psychotherapeutic antidepressant treatments.

The findings reported here add weight to the emerging “hyperconnectivity hypothesis” of depression and support the proposal that increased connectivity may constitute both a biomarker for mood disorder and a potential therapeutic target. The anatomy of the localized pattern of connectivity change described here may explain why efforts to dissociate memory dysfunction from the therapeutic effects of ECT by manipulation of electrode placement and stimulus parameters have largely failed, and it challenges the long-standing notion that the therapeutic and cognitive effects of treatment have distinct neurobiological substrates. The findings thus offer a coherent explanation of the mode of action of ECT in the context of current formulations of the pathophysiology and neuroanatomy of depressive disorder.

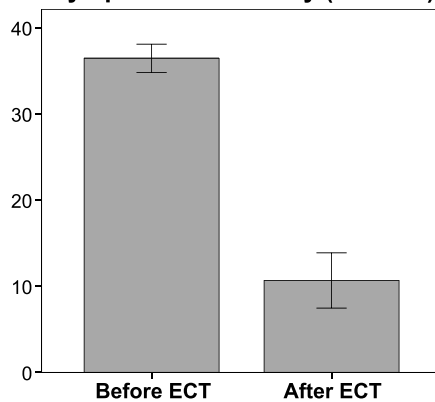
## Methods

**Participants.** Ethical approval was obtained from the National Health Service North East of Scotland Research Ethics Committee, and the study was conducted in accordance with the principles expressed in the Declaration of Helsinki. Participants were recruited from the Royal Cornhill Hospital ECT service. Males and females aged 18 y and older who had been diagnosed

### Functional Connectivity (CHART Analysis)



### Symptomatic Severity (MADRS)



**Fig. 3.** Functional connectivity in severely depressed patients before ECT (displayed in orange) and persisting connectivity after ECT (displayed in cyan), showing a substantial reduction in cortical connectivity after ECT treatment ( $P < 0.001$ , FWE-corrected); z values refer to distance in millimeters from the midline in stereotaxic space [Montreal Neurological Institute standard space]. The observed reduction in functional connectivity following ECT treatment was accompanied by a significant decrease ( $P < 0.001$ ) in depressive symptoms (bar chart).

with severe depression; were receiving ECT on a voluntary basis; were able to give informed consent; had not had ECT in the past 6 mo; were without MRI contraindications; and were without a comorbid psychiatric diagnosis, brain pathology, or a history of strokes were eligible to take part. In total, nine right-handed participants completed the study (6 males and 3 females, mean age = 46.8 y). All had failed to respond to chemical antidepressant treatment, which they continued to take during the study. Four patients were also taking antipsychotic medication (olanzapine or haloperidol), and two of them were also receiving lithium therapy.

**ECT Treatment.** ECT was administered twice weekly until patients' symptoms remitted (mean number of treatments = 8.3) using a brief-pulse, constant-current apparatus (Thymatron DGx, Somatics Inc.). At the first treatment, individual seizure thresholds were determined using standard stimulus dosing techniques, and subsequent treatments were given at twice the seizure threshold. Patients were anesthetized with propofol and given a muscle relaxant (suxamethonium) at each treatment session. All patients received bilateral (bitemporal) ECT electrode placements. The electrodes were placed 4 cm above the midpoint between the lateral angle of the eye and the external auditory meatus. A detailed description of the ECT procedure is provided in *SI Text*.

**Clinical Measure of Depression.** Clinical measures were obtained within 48 h of the first ECT treatment, after the fourth ECT treatment, and after ECT treatment was complete. The MADRS (22) was used to rate depressive symptoms.

**MRI Protocol.** All participants underwent fMRI scanning before ECT treatment and again after ECT treatment had been completed. All scanning was performed on a 3-T Philips system at the Aberdeen Biomedical Imaging Centre, using a standard echo planar imaging sequence. Imaging parameters were as follows: repetition time/echo time = 2,500/30 ms, matrix size = 128 × 128, in-plane resolution = 1.88 × 1.88 mm, slice thickness = 4.5 mm, and total number of fMRI volumes = 240. A simple cognitive task ("virtual" ball-

passing) was used to keep the participant's attention focused during the scan (23). A detailed description of the task is provided in *SI Text*.

**Data Preprocessing.** The statistical parametric mapping software package (SPM8; [www.fil.ion.ucl.ac.uk/spm](http://www.fil.ion.ucl.ac.uk/spm)) was used for fMRI preprocessing, which included realignment, slice timing correction, coregistration, normalization, reslicing to 4 × 4 × 4 mm, and spatial smoothing using an 8-mm FWHM Gaussian isotropic kernel. A low-pass filter (0.125-Hz cutoff frequency) was applied, and a second-order baseline correction was applied by using a set of two cosine functions as linear regressors. A binary mask was defined on the basis of the SPM8 tissue probabilistic map for gray matter, which included all voxels with a gray matter probability greater than 0.2. Pairwise temporal correlations between all voxels in the functional imaging time series within this mask ( $N = 27,600$ ) were computed using Pearson's correlation coefficient, which resulted in an  $N \times N$  correlation matrix **A**.

**Functional Connectivity Analysis.** To identify statistically significant changes in functional connectivity between pre- and posttreatment data, a unique method referred to as cortical hub and related network topology (CHART) analysis was used, which consisted of two stages. First, for each subject and each condition (i.e., pre- and post-ECT treatment), maps of the average global connectivity, also known as weighted global connectivity (WGC), were calculated from the components  $a_{kn}$  of the corresponding correlation matrices **A** according to the method of Cole et al. (24):

$$w_k = \frac{1}{N} \sum_{n=1}^N a_{kn} \quad k = 1 \dots N \quad [1]$$

To obtain statistically significant differences in the WGC between pre- and posttreatment data on a voxel-by-voxel basis, a nonparametric permutation test (SnPM8 toolbox) was used (25). To correct for multiple comparisons, a whole-brain FWE correction was applied (26). A cluster of 12 voxels exhibited a significant decrease in the WGC ( $P < 0.05$ , FWE-corrected)

posttreatment (Fig. 1). Because the WGC is a univariate global measure, it cannot provide any information about the local specificity of these changes. This information was obtained during the second stage of the analysis. The significant cluster of voxels identified during the first stage of the analysis was used as a seed region to determine the associated functional brain networks (i.e., the brain areas to which the seed region was functionally connected before and after ECT treatment). To this end, the average correlation coefficient was calculated for each voxel  $k$  according to

$$\bar{c}_k = \frac{1}{SM} \sum_{i=1}^S \sum_{j=1}^M c_{kij} \quad k = 1 \dots N \quad [2]$$

where  $S$  is the number of subjects,  $M$  is the number of seed voxels, and  $N$  is the total number of voxels. (Note that for each seed voxel, the correlation of the corresponding time series with itself was excluded from the summation.) Two correlation maps, showing connectivity with the seed region pre- and post-ECT treatment, were created. These correlation maps were then converted to binary connectivity maps by applying a correlation threshold of 0.5 ( $P < 0.001$ , FWE-corrected). The FWE-corrected probability was calculated in a Monte Carlo process from a set of 1,000 surrogate data with matching spatial smoothness and temporal autocorrelation; the autocorrelation inherent in the data was estimated by an autoregressive  $AR(1)$  model. Finally, the two binary pre- and posttreatment connectivity maps were combined into a single parametric map, and significant pre- and posttreatment connections were color-coded (Fig. 3). A detailed description of the functional connectivity analysis is provided in [SI Text](#).

- Department of Mental Health and Substance Dependence (2003) *Investing in Mental Health* (World Health Organisation, Geneva).
- UK ECT Review Group (2003) Efficacy and safety of electroconvulsive therapy in depressive disorders: A systematic review and meta-analysis. *Lancet* 361:799–808.
- Baxter LR, Jr., et al. (1989) Reduction of prefrontal cortex glucose metabolism common to three types of depression. *Arch Gen Psychiatry* 46:243–250.
- Bench CJ, et al. (1992) The anatomy of melancholia—focal abnormalities of cerebral blood flow in major depression. *Psychol Med* 22:607–615.
- Drevets WC, et al. (1992) A functional anatomical study of unipolar depression. *J Neurosci* 12:3628–3641.
- Mayberg HS, Lewis PJ, Regenold W, Wagner HN, Jr. (1994) Paralimbic hypoperfusion in unipolar depression. *J Nucl Med* 35:929–934.
- Ressler KJ, Mayberg HS (2007) Targeting abnormal neural circuits in mood and anxiety disorders: From the laboratory to the clinic. *Nat Neurosci* 10:1116–1124.
- Schneider F, et al. (1995) Mood effects on limbic blood flow correlate with emotional self-rating: A PET study with oxygen-15 labeled water. *Psychiatry Res* 61:265–283.
- Mayberg HS, et al. (1999) Reciprocal limbic-cortical function and negative mood: Converging PET findings in depression and normal sadness. *Am J Psychiatry* 156: 675–682.
- Steele JD, Currie J, Lawrie SM, Reid I (2007) Prefrontal cortical functional abnormality in major depressive disorder: A stereotactic meta-analysis. *J Affect Disord* 101:1–11.
- Sheline YI, Price JL, Yan Z, Mintun MA (2010) Resting-state functional MRI in depression unmasks increased connectivity between networks via the dorsal nexus. *Proc Natl Acad Sci USA* 107:11020–11025.
- Lisiecka D, et al. (2011) Neural correlates of treatment outcome in major depression. *Int J Neuropsychopharmacol* 14:521–534.
- McCabe C, Mishor Z (2011) Antidepressant medications reduce subcortical-cortical resting-state functional connectivity in healthy volunteers. *Neuroimage* 57: 1317–1323.
- Biswal BB, et al. (2010) Toward discovery science of human brain function. *Proc Natl Acad Sci USA* 107:4734–4739.

**Methodological Considerations.** In a large number of functional connectivity studies that are typically referred to as “resting-state fMRI,” subjects are instructed “to just relax and not to think about anything specific.” However, as pointed out by Morcom and Fletcher (27), the concept of a resting state or baseline in the human brain is somewhat elusive. In the absence of a specific task, we anticipate that brain activity will exhibit a wider variance because different subjects will be thinking about different things and some may even fall asleep. In this study, we used a simple virtual ball-passing task to keep the subjects’ attention focused. Based on the theoretical arguments put forward by Morcom and Fletcher (27), we anticipate that such a task will reduce the within-group variance, and therefore improve the sensitivity of the between-group comparison.

The majority of connectivity studies use seed-based correlation analyses. In these studies, the anatomical location of the seed region is typically chosen by the researcher to prove or disprove a specific hypothesis. A drawback of this approach is that the researcher’s choice of a specific seed region may bias the outcome of the analysis. The advantage of the CHART method described here is that the choice of the seed region is purely data-driven, and therefore independent of any a priori hypothesis.

**ACKNOWLEDGMENTS.** We thank the ECT team and the patients who volunteered for this study. We also thank the Chief Scientist Office of Scotland for funding this research. S.M., D.J.S., and C.S. acknowledge the support of the Scottish Funding Council through the Scottish Imaging Network: A Platform for Scientific Excellence initiative (SINAPSE).

- Steele JD, Lawrie SM (2004) Segregation of cognitive and emotional function in the prefrontal cortex: A stereotactic meta-analysis. *Neuroimage* 21:868–875.
- Grimm S, et al. (2008) Imbalance between left and right dorsolateral prefrontal cortex in major depression is linked to negative emotional judgment: An fMRI study in severe major depressive disorder. *Biol Psychiatry* 63:369–376.
- Steele JD, Christmas D, Eljamel MS, Matthews K (2008) Anterior cingulotomy for major depression: Clinical outcome and relationship to lesion characteristics. *Biol Psychiatry* 63:670–677.
- Stern WM, Tormos JM, Press DZ, Pearlman C, Pascual-Leone A (2007) Antidepressant effects of high and low frequency repetitive transcranial magnetic stimulation to the dorsolateral prefrontal cortex: A double-blind, randomized, placebo-controlled trial. *J Neuropsychiatry Clin Neurosci* 19:179–186.
- Goldapple K, et al. (2004) Modulation of cortical-limbic pathways in major depression: Treatment-specific effects of cognitive behavior therapy. *Arch Gen Psychiatry* 61: 34–41.
- Hecht D (2010) Depression and the hyperactive right-hemisphere. *Neurosci Res* 68: 77–87.
- Abrams R, Swartz CM, Vedak C (1989) Antidepressant effects of right versus left unilateral ECT and the lateralization theory of ECT action. *Am J Psychiatry* 146: 1190–1192.
- Montgomery SA, Asberg M (1979) A new depression scale designed to be sensitive to change. *Br J Psychiatry* 134:382–389.
- Eisenberger NI, Lieberman MD, Williams KD (2003) Does rejection hurt? An FMRI study of social exclusion. *Science* 302:290–292.
- Cole MW, Pathak S, Schneider W (2010) Identifying the brain’s most globally connected regions. *Neuroimage* 49:3132–3148.
- Nichols TE, Holmes AP (2002) Nonparametric permutation tests for functional neuroimaging: A primer with examples. *Hum Brain Mapp* 15:1–25.
- Nichols T, Hayasaka S (2003) Controlling the familywise error rate in functional neuroimaging: A comparative review. *Stat Methods Med Res* 12:419–446.
- Morcom AM, Fletcher PC (2007) Does the brain have a baseline? Why we should be resisting a rest. *Neuroimage* 37:1073–1082.