

Role of the hippocampus in remembering the past and imagining the future

Larry R. Squire^{a,b,c,d,1}, Anna S. van der Horst^a, Susan G. R. McDuff^b, Jennifer C. Frascino^b, Ramona O. Hopkins^{e,f}, and Kristin N. Mauldin^b

^aVeterans Affairs San Diego Healthcare System, San Diego, CA 92161; Departments of ^bPsychiatry, ^cNeurosciences, and ^dPsychology, University of California at San Diego, La Jolla, CA 92093; ^eDepartment of Psychology and Neuroscience Center, Brigham Young University, Provo, UT 84602; and ^fPulmonary and Critical Care Division, Department of Medicine, Intermountain Medical Center, Murray, UT 84143

Contributed by Larry R. Squire, September 27, 2010 (sent for review August 30, 2010)

It has been proposed that a core network of brain regions, including the hippocampus, supports both past remembering and future imagining. We investigated the importance of the hippocampus for these functions. Five patients with bilateral hippocampal damage and one patient with large medial temporal lobe lesions were tested for their ability to recount autobiographical episodes from the remote past, the recent past, and to imagine plausible episodes in the near future. The patients with hippocampal damage had intact remote autobiographical memory, modestly impaired recent memory, and an intact ability to imagine the future. The patient with large medial temporal lobe lesions had intact remote memory, markedly impaired recent memory, and also had an intact ability to imagine the future. The findings suggest that the capacity for imagining the future, like the capacity for remembering the remote past, is independent of the hippocampus.

episodic memory | semantic memory | medial temporal lobe | remote memory | amnesia

Bilateral damage to medial temporal lobe structures impairs the formation of new memories and also impairs recall of facts, events, and autobiographical experiences that were acquired during the years before the damage occurred (1, 2). This finding suggests that common mechanisms may underlie the ability to form new memories and the ability to recollect recent memories. There has also been interest in the possible link between remembering past experiences and imagining plausible episodes in the future (3). It was noted, for example, that the memory-impaired patient KC was impaired at generating autobiographical details about his past and also could not imagine future autobiographical episodes (4, 5). A link between past remembering and future imagining has received additional support from other patient studies. Thus, the densely amnesic patient DB had difficulty imagining future episodes (6). Similarly, four of five memory-impaired patients with lesions involving the hippocampus were reported to have difficulty constructing future autobiographical scenarios (7). Moreover, elderly individuals who provided fewer specific details about the recent past also provided fewer specific details about the future (8). Last, patients with mild Alzheimer's disease were impaired at providing autobiographical details about both past and future events (9).

Consistent with these observations, neuroimaging studies have described substantial overlap between the brain regions activated when volunteers retrieve past memories and when they imagine future experiences (e.g., refs. 10–14). Schacter et al. (14) suggested that a core network of brain regions supports past remembering and future imagining. The key components of this network are proposed to be the medial prefrontal cortex, posterior regions in medial and lateral parietal cortex, lateral temporal cortex, and the medial temporal lobe including hippocampus (14, 15).

Within this network, the importance of the hippocampus and related medial temporal lobe structures for future imagining is not entirely clear. First, elderly individuals and patients with Alzheimer's disease exhibit a variety of neuropathological changes

(16, 17), and it is therefore difficult to attribute their difficulty in constructing future scenarios to a specific structure. Second, patient KC developed amnesia after a head trauma and has significant damage in frontal, parietal, and occipital cortex (18). Third, the extent of DB's lesion was not described, and it is unclear which structures were damaged (6). Last, the patients with hippocampal damage who were impaired had amnesia resulting from limbic encephalitis (7). Although this condition is known to affect medial temporal lobe structures, patients can exhibit deficits beyond memory in intelligence and executive function (19–21).

To explore these issues further, we tested the capacity for imagining future episodes in five patients with well-characterized, bilateral lesions apparently limited to the hippocampus and in one patient with large bilateral medial temporal lobe lesions that include the hippocampus. We administered the Adapted Autobiographical Interview (8, 22, 23) to patients and age-matched controls and, using the same measures used in previous studies (7, 8), we evaluated their capacity for constructing autobiographical episodes in three time periods: remote memory (before the age of 25 y), recent memory (within the past year), and the capacity to construct plausible autobiographical episodes for the near future.

Results

Both patients and controls were able to provide unique autobiographical memories and to imagine plausible future episodes for most of the cue words (5 to probe the remote past, 5 to probe the recent past, and 10 to probe the future). Fig. 1 shows the mean number of internal and external elements generated for episodes from the remote past, recent past, and future (elements were averaged across all cue words). The data were analyzed separately for the patients with hippocampal lesions and for the patient with large medial temporal lobe lesions (GP). For the internal elements, a two-way ANOVA (hippocampal and control group \times time period) revealed no effect of group [$F(1,11) = 0.1$, $P > 0.1$] or time period [$F(2,11) = 1.1$, $P > 0.1$] but a group \times time period interaction [$F(2,11) = 7.2$, $P < 0.03$]. The interaction reflects the fact that the patients scored similarly to, or even better than, controls for the remote and future time periods but worse than the controls for the recent past. Post hoc tests for each time period revealed a marginal difference between groups for the recent time period [$t(11) = 1.9$, $P = 0.08$].

Patient GP provided as many elements as controls when recalling remote past episodes and when imagining future episodes, but he was markedly impaired at recalling episodes from the recent past [single sample t test vs. controls; $t(7) = 10.3$, $P <$

Author contributions: L.R.S. and K.N.M. designed research; J.C.F. and R.O.H. performed research; A.S.v.d.H., J.C.F., and K.N.M. analyzed data; and L.R.S., A.S.v.d.H., and S.G.R.M. wrote the paper.

The authors declare no conflict of interest.

¹To whom correspondence should be addressed. E-mail: lsquire@ucsd.edu.

This article contains supporting information online at www.pnas.org/lookup/suppl/doi:10.1073/pnas.1014391107/-DCSupplemental.

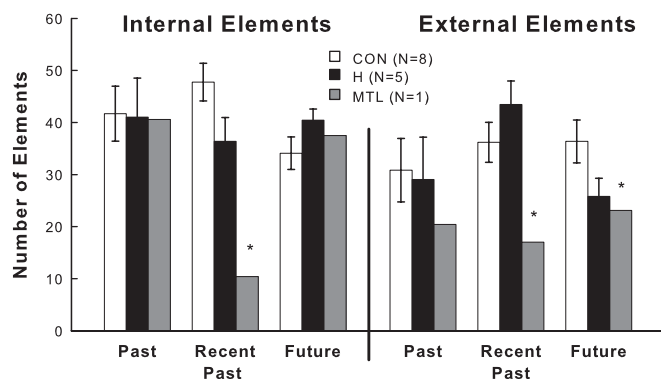


Fig. 1. Mean number of internal and external elements generated for remote past, recent past, and future episodes by patients with lesions limited to the hippocampus (H), a patient with a large medial temporal lobe lesion (MTL), and controls (CON). Internal elements were details provided for the narrative that were part of a remembered or imagined episode. External elements consisted of semantic information or details unrelated to the reported episode. Error bars indicate SEM. * $P < 0.05$ vs. CON.

0.01]. Thus the patients were able to recall detailed autobiographical memories from their early life and to imagine detailed future events, but they had difficulty recalling detailed memories from their recent past.

For the external elements (Fig. 1), a two-way ANOVA (hippocampal group \times time period) revealed no effect of group [$F(1,11) = 0.1, P > 0.10$], an effect of time period [$F(2,11) = 7.4, P < 0.03$], and a marginal group \times time period interaction [$F(2,11) = 3.9, P = 0.08$]. The effect of time period reflects the large number of external elements recalled from the recent past, relative to the remote past and future time periods. Note that the numerical difference between hippocampal patients and controls in the future time period did not reach significance [$t(11) = 1.8, P = 0.10$]. Patient GP did not provide as many external elements as controls in the recent past and the future time periods ($ts > 3.2, Ps < 0.05$).

Narratives were also scored for measures of content for each experiential index [spatial references (SPA), entities present (EP), sensory descriptions (SD), and thought/emotion/actions (TEA)] to determine the quality of the remembered and imagined episodes (Fig. 2). A three-way ANOVA (hippocampal group \times time period \times measure) revealed no effect of group [$F(1,11) = 0.1$] and no interactions involving the group factor ($Ps > 0.5$). Thus, the controls and the patients with hippocampal lesions provided a similar number of elements within each content category, including the spatial category. There was an effect

of time period [$F(2,11) = 9.0, P < 0.01$] due to the greater number of elements provided overall for the recent time period than for the remote past and future time periods. There were also effects of content [$F(3,11) = 11.0, P < 0.01$] and a content \times time period interaction [$F(6,11) = 9.6, P = 0.01$].

GP's narratives included few SDs in all three time periods [$ts(7) > 3.2, P < 0.02$] relative to controls. As expected, because of his severe retrograde amnesia, GP also provided few elements from the recent time period for each of the four content measures [$ts(7) > 2.7, Ps < 0.03$]. Notably, however, GP did provide as many SPA, EP, and TEA elements as controls when recalling remote past episodes and when imagining future episodes.

The patients with hippocampal lesions tended to repeat themselves within their narrative episodes (Fig. 3). Presumably, these effects occurred because memory impairment made it difficult during delivery of narratives to remember what had been said earlier in the narrative. For internal elements, a two-way ANOVA (hippocampal group \times time period) revealed an effect of group [$F(1,11) = 32.6, P < 0.01$], no effect of time period [$F(2,11) = 1.33$] and no group \times time period interaction [$F(2,11) = 0.14$]. The results were similar for external elements (Fig. 3). A two-way ANOVA (hippocampal group \times time period) revealed an effect of group [$F(1,11) = 7.0, P < 0.03$] but no effect of time period [$F(2,11) = 0.9$] and no group \times time interaction [$F(2,11) = 0.04$]. In the case of internal elements GP, like the hippocampal patients, repeated more phrases than controls in every time period [$ts(7) > 2.7, Ps < 0.03$]. However, his repetitions of external elements did not differ noticeably from controls.

There was no difference in ratings of vividness, emotion, and personal significance between hippocampal patients and controls (patients, 4.2, 3.8, and 4.2; controls, 4.1, 3.7, and 3.8, respectively). Indeed, none of the comparisons approached significance for any time period [$ts(11) < 1.8, Ps > 0.1$]. Hippocampal patients and controls also used a similar number of words to relate each narrative (repeated phrases were excluded from this analysis). Averaged across time periods, the patients used 262.5 ± 21.1 words and the controls used 243.5 ± 13.8 words. The results were the same when the word count was calculated separately for each time period [$ts(11) < 1.0, Ps > 0.3$]. GP gave high ratings for vividness, emotion, and personal significance across all time periods [mean for the three ratings across time periods was 4.8; $t(7) = 8.2, P < 0.01$]. With respect to word count, his remote past and future narratives (excluding repeated phrases) involved a similar number of words as controls (remote past: control 220.9 ± 23 ; GP 219; future: control 213.9 ± 16.4 ; GP 223.6). However, GP used fewer words than controls to relate narratives from the recent past [control 295.5 ± 22.1 ; GP 232.8; $t(7) = 2.8, P < 0.03$], presumably because of his severe retrograde amnesia.

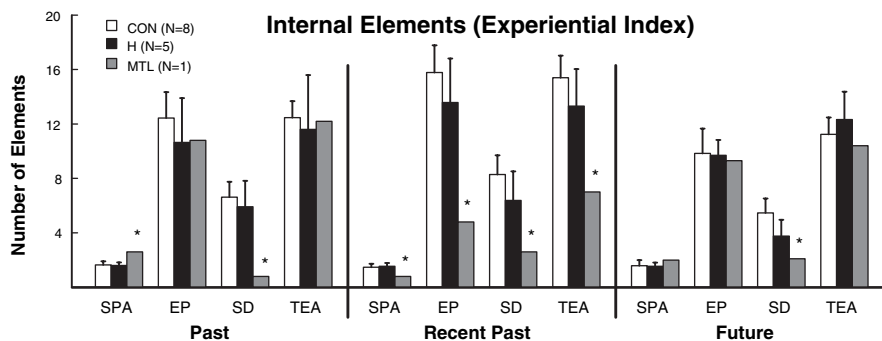


Fig. 2. Mean number of internal elements in each category of experiential index generated for remote past, recent past, and future episodes by patients with lesions limited to the hippocampus (H), a patient with a large medial temporal lobe lesion (MTL), and controls (CON). Categories SPA, EP, SD, and TEA are defined in *Results*. Error bars indicate SEM. * $P < 0.05$ in comparison with CON.

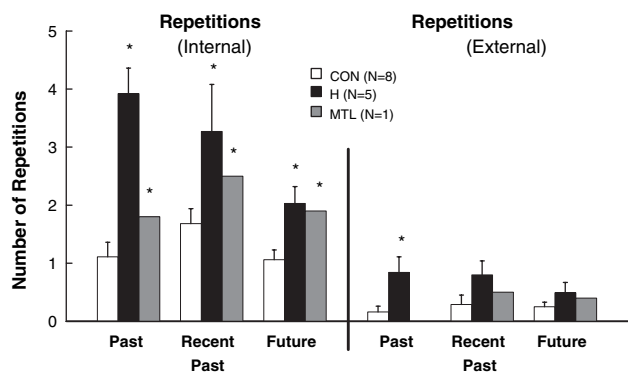


Fig. 3. Mean number of phrases repeated during narration of remote past, recent past, and future episodes by patients with lesions limited to the hippocampus (H), a patient with a large medial temporal lobe lesion (MTL), and controls (CON). Error bars indicate SEM. * $P < 0.05$ in comparison with CON.

Discussion

Patients with circumscribed hippocampal lesions and one patient with large medial temporal lobe lesions were asked to recollect autobiographical memories from both the recent and remote past and to imagine plausible episodes in the future. Similar to what was found in our previous studies of autobiographical memory (22, 24), the patients with hippocampal damage had intact remote autobiographical memory and modestly impaired recent memory. In addition, we found that when the patients imagined future autobiographical episodes, they provided as many total details as controls (Fig. 1), as well as a similar number of details in each content category (Fig. 2).

The findings for the profoundly amnesic patient GP were particularly instructive. GP had intact remote autobiographical memory but was markedly impaired when recalling recent memory, similar to what has been described previously for this patient (22, 24). Despite this severe impairment in recollecting from the recent past, GP performed similarly to controls when he constructed future personal events (Fig. 1), and he provided as many details as controls for nearly every content category (Fig. 2). Unlike patients with hippocampal lesions, GP provided fewer sensory descriptions than controls in all three time periods (Fig. 2). GP also provided fewer external elements in his narratives about the recent past and the future than did controls (Fig. 1).

The hippocampal patients as well as GP tended to repeat themselves when constructing narratives in all three time periods (Fig. 3). This marked impairment presumably resulted from their memory deficit, and it stands in sharp contrast to the intact ability of these patients to imagine future episodes. Hippocampal patients and controls also used a similar number of words to describe their episodes. GP did use fewer words than controls to describe episodes from the recent past, presumably owing to his severe retrograde amnesia covering that time period.

Our findings support the idea that only recall from the recent past depends on the hippocampus and that, if the core network of brain regions described by Schacter et al. (14) is largely intact except for the hippocampus (specifically the precuneus/retrosplenial cortex, medial prefrontal cortex, lateral parietal cortex, and lateral temporal cortex), then remote memory and future imagining will be intact.

In related work, older adults produced less autobiographical detail than younger adults when describing both past and future events (8). There was also a significant positive correlation between the richness of these narratives and paired-associate learning, a standard test of medial temporal lobe function. This finding raised the possibility that age-related loss of hippocampal function might underlie the impaired ability to remember the

past and imagine the future. This possibility seems unlikely because the patients in the present study are all severely impaired at paired-associate learning but were nonetheless intact at future imagining. Another possibility, suggested by Addis et al. (8), and perhaps more likely in light of the present findings, is that impaired future imagining depends on age-related changes in prefrontal cortex. Consistent with this idea, there is evidence that the richness of autobiographical remembering and future imagining depends importantly on factors unrelated to memory itself (25).

Hassabis et al. (7) assessed the importance of the hippocampus for future imagining by testing patients with bilateral hippocampal damage. Four of the five patients tested were impaired. It is notable that the procedure followed in that study differed from our own. In that study, participants were given a scenario to use in constructing a future episode (e.g., “Imagine you are lying on a white sandy beach in a beautiful tropical bay”). In contrast, following Addis et al. (8), we asked patients to describe whatever personal episodes they could produce in response to single cue words. It is unclear whether these differences in procedure are significant for understanding our different findings.

It is also notable that all four of the patients in the earlier study who were impaired in imagining the future became amnesic as a result of limbic encephalitis (7). Three of these patients had limbic encephalitis associated with elevated voltage-gated potassium channel antibodies (VGKC-Abs), and the remaining patient had limbic encephalitis in the absence of VGKC-Abs. The two conditions have been reported to have very similar characteristics (20).

Limbic encephalitis presents with a complex clinical picture and with brain abnormalities that extend beyond medial temporal lobe structures (e.g., refs. 19–21, 26). For example, Schott et al. (21) documented whole-brain cortical atrophy in the case of one individual with VGKC-Ab limbic encephalitis. Their patient sustained a 22.6% (left) and 39.6% (right) reduction in hippocampal volume, as well as a decrease in whole brain volume by 11.4% over the course of 6 mo.

Patients with limbic encephalitis can also perform poorly on tests of frontal lobe function (20, 21). They may also confabulate (19, 26, 27), be confused (19, 21), have seizures (20, 21), manifest personality changes (19, 20, 27), and have EEG abnormalities in areas outside the medial temporal lobe (21). Patients with elevated serum VGKC-Abs can even present with frontotemporal-like dementia (27, 28). These features of limbic encephalitis are associated mainly with its acute presentation. Nevertheless, because the condition presents initially with signs of broad cognitive impairment, it is possible that even patients who have stabilized with treatment can have persisting dysfunction in regions other than the medial temporal lobe.

Although patients in the study by Hassabis et al. (7) were reported to perform within the normal range on tests of language, perception, verbal fluency, and executive functioning, there are suggestions that the impairment extended beyond memory in some of the cases. For example, in a separate report, patient P03 was reported to have persisting personality change associated with his limbic encephalitis (20). Additionally, in a different report patient P04 was described as having verbal and performance intelligence quotient (IQ) in the normal range but was considered to have some intellectual deficiency in view of his estimated high premorbid IQ (29). Last, patient P02 was reported elsewhere to have “some generalized atrophy” (not additionally specified) and obtained an IQ score in the low average range (30).

The patient in Hassabis et al. (7) who was not impaired in imagining the future (P01) had brain damage as a result of a different condition: meningoencephalitis and recurrent meningitis. This individual had anterograde and retrograde amnesia and was reported to have a substantial loss of hippocampal volume (48.8% reduction in the left and 46.2% reduction in the right), and bilateral abnormalities in the occipital lobes. It was

noted elsewhere that patient P01 also has significant volume reduction in the amygdala bilaterally and in left entorhinal cortex (31). One possibility is that residual right hippocampal tissue, as suggested by fMRI activity thought to be localized to that region, might account for P01's capacity for future imagining (7). Alternatively, other work suggests that hippocampal volume reduction of more than 40% reflects nearly complete loss of hippocampal neurons (32). If so, then for P01 future imagining was not hippocampus-dependent.

Two other studies of future imagining each involved a young adult with developmental amnesia (33, 34). Both patients were reported to have approximately a 50% reduction of hippocampal volume bilaterally, but they performed differently on the tests. Jon (33) imagined future scenarios as well as controls, but HC (34) was impaired. These different results do not suggest a single view and do not illuminate possible differences between developmental amnesia and adult-onset amnesia. Additional study of developmental amnesia will be needed to weigh the possible importance of either residual hippocampal tissue or damage to structures beyond the hippocampus.

In any case, it is clear that patients with adult-onset memory impairment due to limbic encephalitis are impaired at imagining the future (7). In view of our findings of intact future imagining in patients with circumscribed hippocampal damage, and even in a patient with large medial temporal lobe lesions and virtually complete loss of hippocampus, it seems doubtful that impaired future imagining can be attributed specifically to hippocampal damage. We suggest instead that difficulty imagining the future is caused by damage to structures other than the hippocampus that lie within the core network described by Schacter et al. (14), structures such as medial frontal cortex and lateral temporal cortex that are known to be important for remembering both recent and remote autobiographical episodes (35).

Materials and Methods

Participants. Six memory-impaired patients participated (Table 1). Of these, five have damage thought to be limited to the hippocampus. GW and RS became amnesic after drug overdoses and associated respiratory failure. JRW became amnesic after cardiac arrest. KE became amnesic after an episode of ischemia associated with kidney failure and toxic shock syndrome. LJ (the only female) became amnesic during a 6-mo period in 1988 with no known precipitating event. Her memory impairment has remained stable since that time. Estimates of medial temporal lobe damage were based on quantitative analysis of MR images of patients compared with data for 19 controls (11 for LJ) (32, 36). GW, RS, JRW, KE, and LJ have average bilateral reductions in hippocampal volume of 48%, 33%, 44%, 49%, and 46%, respectively (all values > 3 standard deviations from the control mean). The volume of parahippocampal gyrus (temporopolar, perirhinal, entorhinal, and parahippocampal cortices) is reduced by 12%, 1%, 6%, 17%, and -8%, respectively (all values within two standard deviations of the control mean).

One patient (GP) has severe memory impairment resulting from viral encephalitis. GP has demonstrated virtually no new learning since the onset of his amnesia, and during repeated testing over many weeks he does not recognize that he has been tested before (37). GP has average bilateral

reductions in hippocampal volume of 96%. The volume of the parahippocampal gyrus is reduced by 92%. Nine coronal MR images from each of the six patients are available as Fig. S1.

Eight healthy volunteers (two female) served as controls for the memory-impaired patients. Controls averaged 62.8 ± 3.6 y of age (patients, 57.7 ± 4.3 y) and had 15.3 ± 0.6 y of education (patients, 12.9 ± 0.7 y).

Test of Autobiographical Memory. We administered the Adapted Autobiographical Interview to test autobiographical memory as described previously (8). Participants were asked to recall five autographical episodes from each of two past time periods: remote past (before the age of 25 y) and recent past (within the last year). They were instructed to relate single events that happened on a particular day at a particular place and time. Participants were also asked to invent 10 plausible autobiographical episodes, appropriate for the near future (during the next year). Following Addis et al. (8), they were instructed that they could be creative but not unrealistic ("don't tell me about going to the moon, for example"). "You should imagine or invent a scenario that hasn't happened to you before." For each episode (past and future), a noun cue was provided to facilitate recall (e.g., "tree"), although the episode could be unrelated to the word. It was emphasized that the episode imagined for the future should not be similar to an actual past event (to discourage participants from remembering a past event and then recasting it for the future (38)). Three minutes were allowed for recollecting or imagining each event. Probing was used to elicit additional details about the episode (e.g., "Is there anything else you can tell me about that?"). Probing did not introduce new details that had not already been mentioned by the participant. If the participant strayed from recalling a specific episode, the examiner reminded the participant to focus on one particular event. When each narrative was completed, participants used a five-point rating scale to rate the level of vividness, emotion, and personal significance of the episode.

Scoring. Interviews were recorded and transcribed. Transcripts of narratives were then scored beginning at the point when the participant began to recall a single episode. Narratives were scored in three different ways. First, narratives were divided into "elements," which were defined as a piece of information, observation, statement, or thought (8, 22). Each element was then categorized as "internal" or "external." Internal elements consisted of episodic information relating directly to the autobiographical event being recalled. External elements consisted of semantic information (factual information that formed background to the narrative) as well as episodic detail that was not part of the autobiographical event being recalled.

Second, we applied the experiential index as described by Hassibis et al. (7). Each episode was scored for four content measures: EP, SD, SPA, and TEA (defined in *Results*). EP provided a count of the distinct entities within an episode (e.g., people, animals, objects). SD was a count of statements that described an entity (e.g., "she is short"), as well as other descriptors (e.g., "windy"). SPA counted statements that described the positions of entities within the episode (e.g., "nearby"), directions relative to the participant's vantage point (e.g., "in front of me"), or measurements (e.g., "about 10 feet long"). TEA counted thoughts (e.g., "I thought about the boy"), emotional feelings (e.g., "I was angry"), or actions (e.g., "she ran").

Third, the number of repetitions of complete phrases or complete ideas was counted within each episode whenever the phrase or idea was repeated using the same or very similar words. Repeated content did not contribute to the scores obtained using the first two scoring methods, so that the scores for the narratives reflected unique content (not scores artificially elevated by repetition).

Table 1. Characteristics of memory-impaired patients

Patient	Age (y)	Education (y)	WAIS-III IQ	Attention	WMS-R			
					Verbal	Visual	General	Delay
GP	62	16	98	102	79	62	66	<50
GW	49	12	108	105	67	86	70	<50
JRW	45	12	90	87	65	95	70	<50
KE	67	13.5	108	114	64	84	72	55
LJ	71	12	101	105	83	60	69	<50
RS	52	12	99	99	85	81	82	<50

The Wechsler Adult Intelligence Scale-III (WAIS-III) and the Wechsler Memory Scale-Revised (WMS-R) yield mean scores of 100 in the normal population, with a standard deviation of 15. The WMS-R does not provide numerical scores for individuals who score <50. IQ scores for JRW and RS are from the WAIS-R.

We also counted the number of words used to relate each narrative: words that were part of the episode being remembered (i.e., internal elements) and also the total number of words used, beginning at the point when participants began to recall a specific episode (i.e., internal plus external elements).

Reliability of Scoring. The narratives of all 14 participants were first scored for internal and external elements by one rater. A second independent rater also scored 25% of the narratives from each time period. For the content measures in the experiential index, one rater scored all of the narratives, and a second independent rater scored 67% of the narratives. All narratives were scored

for repetitions by two independent raters. Raters were blind to the hypothesis of the study. Across the three different ways of scoring, the two raters scored details and repetitions similarly (correlations ranged from 0.85 to 0.98).

ACKNOWLEDGMENTS. We thank Ashley Knutson, Christine Smith, Annette Jeneson, Zhuang Song, and Veronica Galván for their assistance. This work was supported by the Medical Research Service of the Department of Veterans Affairs, National Institute of Mental Health Grant MH 24600, the Metropolitan Life Foundation, and National Institute on Aging Grant T32 AG26757.

- Eichenbaum H, Cohen NJ (2001) *From Conditioning to Conscious Recollection: Memory Systems of the Brain* (Oxford University Press, New York).
- Squire LR, Stark CEL, Clark RE (2004) The medial temporal lobe. *Annu Rev Neurosci* 27: 279–306.
- Tulving E (1985) Memory and consciousness. *Can Psychol* 26:1–12.
- Rosenbaum RS, Gilboa A, Levine B, Winocur G, Moscovitch M (2009) Amnesia as an impairment of detail generation and binding: Evidence from personal, fictional, and semantic narratives in K.C. *Neuropsychologia* 47:2181–2187.
- Tulving E (2002) Episodic memory: From mind to brain. *Annu Rev Psychol* 53:1–25.
- Klein SB, Loftus J, Kihlstrom JF (2002) Memory and temporal experience: The effects of episodic memory loss on an amnesic patient's ability to remember the past and imagine the future. *Soc Cognition* 20:353–379.
- Hassabis D, Kumaran D, Vann SD, Maguire EA (2007) Patients with hippocampal amnesia cannot imagine new experiences. *Proc Natl Acad Sci USA* 104:1726–1731.
- Addis DR, Wong AT, Schacter DL (2008) Age-related changes in the episodic simulation of future events. *Psychol Sci* 19:33–41.
- Addis DR, Sacchetti DC, Ally BA, Budson AE, Schacter DL (2009a) Episodic simulation of future events is impaired in mild Alzheimer's disease. *Neuropsychologia* 47: 2660–2671.
- Addis DR, Wong AT, Schacter DL (2007) Remembering the past and imagining the future: Common and distinct neural substrates during event construction and elaboration. *Neuropsychologia* 45:1363–1377.
- Addis DR, Pan L, Vu MA, Laiser N, Schacter DL (2009b) Constructive episodic simulation of the future and the past: Distinct subsystems of a core brain network mediate imagining and remembering. *Neuropsychologia* 47:2222–2238.
- Okuda J, et al. (2003) Thinking of the future and past: The roles of the frontal pole and the medial temporal lobes. *Neuroimage* 19:1369–1380.
- Szpunar KK, Watson JM, McDermott KB (2007) Neural substrates of envisioning the future. *Proc Natl Acad Sci USA* 104:642–647.
- Schacter DL, Addis DR, Buckner RL (2007) Remembering the past to imagine the future: The prospective brain. *Nat Rev Neurosci* 8:657–661.
- Schacter DL, Addis DR (2009) On the nature of medial temporal lobe contributions to the constructive simulation of future events. *Philos Trans R Soc Lond B Biol Sci* 364: 1245–1253.
- Burke SN, Barnes CA (2006) Neural plasticity in the ageing brain. *Nat Rev Neurosci* 7: 30–40.
- Price DL (1986) New perspectives on Alzheimer's disease. *Annu Rev Neurosci* 9: 489–512.
- Rosenbaum RS, et al. (2005) The case of K.C.: Contributions of a memory-impaired person to memory theory. *Neuropsychologia* 43:989–1021.
- Harrower T, Foltynie T, Kartsounis L, De Silva RN, Hodges JR (2006) A case of voltage-gated potassium channel antibody-related limbic encephalitis. *Nat Clin Pract Neurol* 2:339–343, quiz 343.
- Samarasekera SR, et al. (2007) Course and outcome of acute limbic encephalitis with negative voltage-gated potassium channel antibodies. *J Neurol Neurosurg Psychiatry* 78:391–394.
- Schott JM, et al. (2003) Amnesia, cerebral atrophy, and autoimmunity. *Lancet* 361: 1266.
- Kirwan CB, Bayley PJ, Galván VV, Squire LR (2008) Detailed recollection of remote autobiographical memory after damage to the medial temporal lobe. *Proc Natl Acad Sci USA* 105:2676–2680.
- Levine B, Svoboda E, Hay JF, Winocur G, Moscovitch M (2002) Aging and autobiographical memory: dissociating episodic from semantic retrieval. *Psychol Aging* 17:677–689.
- Bayley PJ, Hopkins RO, Squire LR (2006) The fate of old memories after medial temporal lobe damage. *J Neurosci* 26:13311–13317.
- Gaesser B, Sacchetti CD, Addis DR, Schacter DL Characterizing age-related changes in remembering the past and imagining the future. *Psychol Aging*, in press.
- Kartsounis LD, de Silva R (2010) Unusual amnesia in a patient with VGKC-Ab limbic encephalitis: A case study. *Cortex*, in press.
- Toosy AT, et al. (2008) Functional imaging correlates of fronto-temporal dysfunction in Morvan's syndrome. *J Neurol Neurosurg Psychiatry* 79:734–735.
- McKeon A, et al. (2007) Potassium channel antibody associated encephalopathy presenting with a frontotemporal dementia like syndrome. *Arch Neurol* 64: 1528–1530.
- Hartley T, et al. (2007) The hippocampus is required for short-term topographical memory in humans. *Hippocampus* 17:34–48.
- Maguire EA, Nannery R, Spiers HJ (2006) Navigation around London by a taxi driver with bilateral hippocampal lesions. *Brain* 129:2894–2907.
- Aggleton JP, et al. (2005) Sparing of the familiarity component of recognition memory in a patient with hippocampal pathology. *Neuropsychologia* 43:1810–1823.
- Gold JJ, Squire LR (2005) Quantifying medial temporal lobe damage in memory-impaired patients. *Hippocampus* 15:79–85.
- Maguire EA, Vargha-Khadem F, Hassabis D (2010) Imagining fictitious and future experiences: Evidence from developmental amnesia. *Neuropsychologia* 48: 3187–3192.
- Kwan D, Carson N, Addis DR, Rosenbaum RS (2010) Deficits in past remembering extend to future imagining in a case of developmental amnesia. *Neuropsychologia* 48:3179–3186.
- Squire LR, Bayley PJ (2007) The neuroscience of remote memory. *Curr Opin Neurobiol* 17:185–196.
- Bayley PJ, Gold JJ, Hopkins RO, Squire LR (2005b) The neuroanatomy of remote memory. *Neuron* 46:799–810.
- Bayley PJ, Frascino JC, Squire LR (2005a) Robust habit learning in the absence of awareness and independent of the medial temporal lobe. *Nature* 436:550–553.
- Addis DR, Musicaro R, Pan L, Schacter DL (2010) Episodic simulation of past and future events in older adults: Evidence from an experimental recombination task. *Psychol Aging* 25:369–376.